

ORIGINAL ARTICLE

Refractory sickle cell leg ulcer: is heparan sulphate a new hope?

Shady Hayek¹, Saad Dibo¹, Joe Baroud¹, Amir Ibrahim¹ & Denis Barritault²¹ Plastic and Reconstructive Surgery, Private Practice, American University of Beirut – Medical Center, Beirut, Lebanon² Laboratoire CRRET CNRS, University Paris Est Creteil, Paris, France**Key words**

Caciqliq20; Glucose amino glycans; Heparan sulphate; Sickle cell ulcer; Ulcer

Correspondence to

S Hayek, MD
Assistant Professor of Surgery
Plastic and Reconstructive Surgery
Private Practice
Beirut
Lebanon
E-mail: hayek010@umn.edu

Hayek S, Dibo S, Baroud J, Ibrahim A, Barritault D. Refractory sickle cell leg ulcer: is heparan sulphate a new hope?. *Int Wound J* 2014; doi: 10.1111/iwj.12217**Abstract**

Patients with sickle cell disease are known to have recurrent lower extremity ulcers that have a high pain score and are resistant to conventional means of wound therapy. This study reports the successful use of synthetic heparan sulphate (Caciqliq20[®], OTR3, Paris, France) in the treatment of a sickle cell ulcer that had failed to respond to several other means of treatment. Therapeutic success was assessed by complete wound coverage and vast improvement in pain score. This is the first study to report use of heparan sulphate in sickle cell ulcers.

Introduction

Sickle cell disease (SCD) is caused by the production of an abnormal sickle shaped haemoglobin that is moderated by the persistence of foetal haemoglobin (1). The polymerisation of this abnormal haemoglobin results in clumping and obstruction of small vessels leading to ischaemic changes especially in areas with poor or limited blood supply such as the ankles and the anterior tibial areas (1–3). This results in recurrent skin ulcers that are sometimes resistant to conventional wound management modalities (1–3). It is estimated that skin ulcers occur in 25–75% of patients with SCD (1–12). Historically the treatment consists of transfusions, local wound care and skin grafting with a high recurrence rate and long hospital stays (1,7).

In this article we report a case of recurrent sickle cell ulcer refractory to all conservative and surgical measures in a 25-year-old woman, who was successfully treated by repeated topical application of a newly developed heparan sulphate solution marketed as Caciqliq20[®] (OTR3, Paris, France).

Case description

The patient was a 25-year-old woman who was referred by her haematologist in 2005 for a non-healing sickle cell ulcer over the lateral aspect of her left ankle. Her haemoglobin analysis showed a pattern compatible with homozygous SCD also known as sickle β -thalassemia (Table 1). At that time she was treated with Promogran[®] (Johnson & Johnson Medical, Skipton, UK), and the ulcer healed over a few weeks time.

She was doing fine on regular follow ups until she came back in November of 2008 with recurrence of the same ulcer. Her pain level was estimated to be 10 on the visual analogue scale (VAS). The wound was dry and showed no signs of infection. She was started on moist wound therapy to no avail, followed by Promogran[®] (Johnson & Johnson) for 8 weeks without any improvement. In December of 2009 she underwent tangential excision of the ulcer bed followed by full thickness skin graft application a few days later when the bed had showed good granulation tissue growth. After a 2-week period of unremarkable postoperative course, a small ulcer started to appear at the edge, enlarging over a short time to cover the whole original wound size. The wound was treated conservatively and the patient received several transfusions that helped slow the growth of the ulcer, failing to revert it into

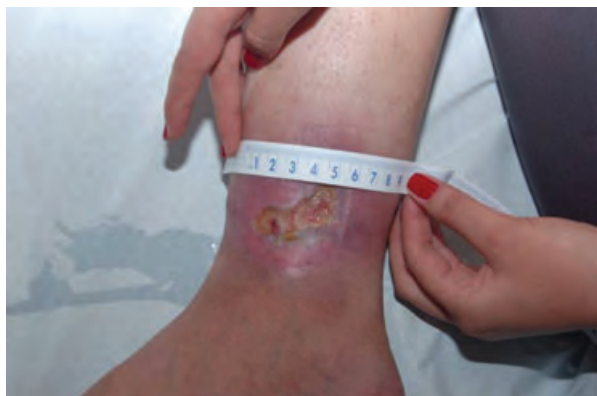
Key Messages

- this is the first case report of using heparan sulphate to treat a chronic and difficult-to-heal ulcer secondary to a sickle cell disease
- it aims at shedding the light on this possible new treatment modality that seems encouraging in this difficult pathology
- despite the fact that this is a single-case report, it would be of benefit to look at the experience of other physicians in this field and especially their experience in using heparan sulphate for such difficult wounds

Table 1 Haemoglobin fractions

Test	Result	Reference
Haemoglobin fractions		
HbF	17.1%	<1.0
HbA2	4.6%	1.5–3.2
HbA	2.5%	
HbS	74.0%	
HbC	0	
HbD	0	
Hb pattern	SS*	

*Compatible with sickle cell disease

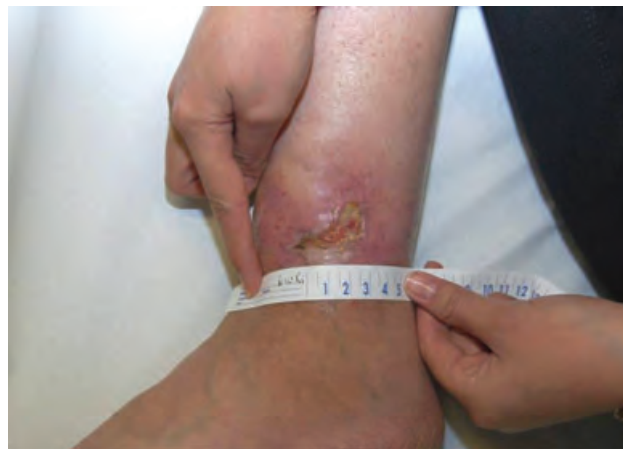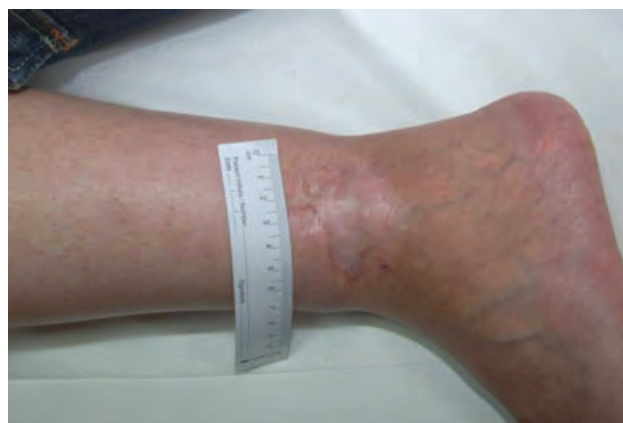**Figure 1** The patient's ulcer before the first application of Caciqliq20[®].

a healing wound. Vacuum assisted closure device attenuated the pain to a level of 7 on the VAS but the wound remained resistant to closure. An unsuccessful trial of mist therapy accompanied by an exchange transfusion was also attempted by another physician. The availability of topical heparan sulphate (Caciqliq20[®], OTR3) as an alternative treatment option was discussed with the patient. She was informed that it had not yet been tried on sickle cell ulcers, but that there was some promising evidence in arterial ischaemic ulcers. The patient agreed to use it (Figure 1 showing the ulcer location and size before application of Caciqliq20[®]). The treatment consisted of topical application of the heparan sulphate solution to the wound twice weekly for 5 minutes each time, alternating with a normal saline moist dressing changed on daily basis. The pain level decreased to 2–3 on the VAS over the second week and to 0 thereafter. The wound gradually improved (Figure 2) after that and it healed completely over a total period of 8 weeks of application of topical heparan sulphate (Figure 3). The patient was followed up in the clinic for a period of 12 months and the wound remained covered with a stable tissue (Figure 4) coupled with a level 0 pain on the VAS.

Discussion

Glycosaminoglycans (GAGs) are usually divided into two groups (8,9):

1. Intracellular or membrane associated such as syndecans and glypicans

**Figure 2** The patient's ulcer 3 weeks after the first application of Caciqliq20[®].**Figure 3** The patient's ulcer 8 weeks after the first application of Caciqliq20[®].

2. Extracellular such as perlecan and agrin

The different types of GAGs are classified according to the amount of sulphation and the size of the oligosaccharide attached to them (8,9). These molecules have been found to be crucial for several cellular and intercellular processes including inflammation (10–12), neurodegeneration (13), angiogenesis (14), cardiovascular diseases (15), cancer (16) and infectious diseases (17–19). Heparin and heparan sulphate are GAGs that have 1–4 linked uronic acid and glycosamine with varying amounts of sulphation allowing them to be involved in several activities including binding to anti-thrombin producing the anticoagulant activity of Heparin (9,20). Recently, the therapeutic value of heparin and heparan sulphate in wound healing has been more appreciated because of their ability to bind, activate and immobilise a variety of growth factors, chemokines and metalloproteinases (21,22). A molecule called OTR4120, structurally similar to heparin but ten times less potent as an anticoagulant (23), has been shown to enhance wound healing in animal models for peripheral nerve injury (24), burn skin (25), chronic ulcers (26) and cutaneous wound

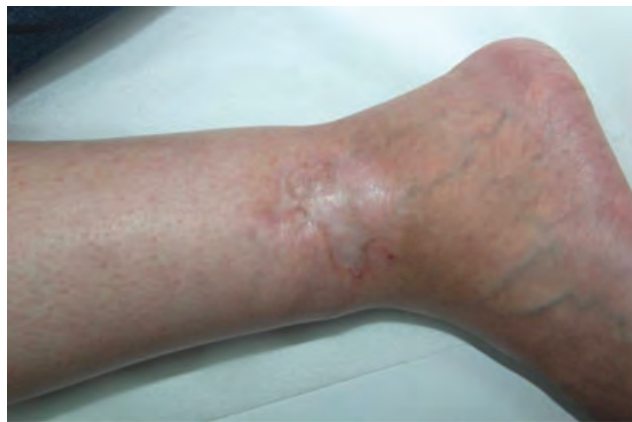

Figure 4 The patient's ulcer 12 months after the wound has healed completely.

repair in rats (27). One of the approaches to treat chronic non-healing wounds is to replace the GAGs in the extracellular matrix in order to restore tissue homeostasis and to protect the wound from further damage (28). Caciqliq20[®] is a skin specific synthetic bioengineered heparan sulphate GAG mimetic which replaces the heparan sulphate that was destroyed in the wound, restoring the extracellular matrix scaffold and allowing key interactions with growth factors to occur (28). Moreover, synthetic heparan sulphate mimetic is resistant to destruction by endoglycosidase, making it efficient in restoring the extracellular matrix by binding to heparan-binding sites that become available when the endogenous heparan sulphate is destroyed by heparanase activation (28–30).

Earlier studies have shown that this heparan sulphate mimetic promotes wound healing both in vivo and in vitro (28). In vitro, it has been shown to enhance angiogenesis by modulating vascular endothelial growth factor (VEGF) and collagen-type expression via fibroblast growth factor 2 (FGF-2) and transforming growth factor β 1 (TGF- β 1) (31–34). In vivo, this molecule was able to induce angiogenesis in ischaemic, cardiac and skeletal muscles (31,32), and to improve wound healing, decrease inflammation and improve wound quality in mice with skin ulcers (34,35). Such effects were observed in several wound types including drug-induced skin ulcers, burn wounds, irradiation-induced wounds, post-surgery wounds and pressure-induced wounds (25,27,36,37). In 2008, Barritault *et al.* presented during the second World Union of Wound Healing Societies meeting in Toronto their first results on humans treated with Caciqliq20[®] (38). In this pilot study they studied 15 chronic arterial ulcers to which they applied Caciqliq20[®]. They reported that at 1 month post application 80% of the ulcers improved and the size reduction was reported to be between 12% and 100% with good tolerance and reduced pain. Of the three patients (20%) who did not benefit from the medication, two died and the third underwent amputation (38). In 2011, Suzan Groah from Washington DC reported on a similar study carried out in an underserved metropolitan area on patients with chronic ulcers ranging in duration between 2.5 and 10 years (28). The researchers in this study were able to show that 22%

of the participants had complete healing in 1 month (28). Seven patients in this study had pressure ulcers and spinal cord paralysis representing a high-risk group and indicating the level of recalcitrant wounds that were being treated in the study (28). Despite all these factors the researchers were able to show that at least for the first three sessions, the decrease in the wound size was close to the normal rate for healthy acute wounds (28).

Another important setback in chronic wounds in general and sickle cell ulcers in specific is pain. Groah *et al.* reported in their study that the pain level decreased profoundly as measured by two different tools (28). In our patient, the same decrease in pain level was noted from the first session of application. This decrease in pain was even noticed before any clinically visual changes in the wound size were even noted. The authors propose that this decrease in pain might represent a decrease in the level of inflammatory components of the wound, a theory yet waiting to be proven.

To our knowledge, this is the first case study using Caciqliq20[®] for treating sickle cell ulcers. Several treatment options for these ulcers exist in the literature. Nevertheless, they all share a high rate of recurrence and are associated with high failure rates (1,7). Treatment with Caciqliq20[®] might set a new horizon, but are yet to be studied in future randomised prospective trials.

References

1. Cackovic M, Chung C, Bolton LL, Kerstein MD. Leg ulceration in the sickle cell patient. *J Am Coll Surg* 1998;**187**:307–9.
2. McMahon L, Tamary H, Askin M, Adams-Graves P, Eberhardt RT, Sutton M, Wright EC, Castaneda SA, Faller DV, Perrine SP. A randomized phase II trial of Arginine Butyrate with standard local therapy in refractory sickle cell leg ulcers. *Br J Haematol* 2010;**151**:516–24.
3. Dampier C, LeBeau P, Rhee S, Lief S, Kesler K, Ballas S, Rogers Z, Wang W, Comprehensive Sickle Cell Centers (CSCC) Clinical Trial Consortium (CTC) Site Investigators. Health-related quality of life in adults with sickle cell disease (SCD): a report from the comprehensive sickle cell centers clinical trial consortium. *Am J Hematol* 2011;**86**:203–5.
4. Walshe MM, Milner PF. The management of leg ulcers in sickle cell anaemia. *West Indian Med J* 1967;**16**:10–6.
5. Gueri M, Serjeant GR. Leg ulcers in sickle-cell anaemia. *Trop Geogr Med* 1970;**22**:155–60.
6. Karayalcin G, Rosner F, Kim KY, Chandra P, Aballi AJ. Sickle cell anemia- clinical manifestations in 100 patients and review of the literature. *Am J Med Sci* 1975;**269**:51–68.
7. Wolfort FW, Krizek TJ. Skin ulceration in sickle cell anemia. *Plast Reconstr Surg* 1969;**43**:71–7.
8. Cole CL, Hansen SU, Barath M, Rushton G, Gardiner GM, Avizienyte E, Jayson GC. Synthetic heparan sulfate oligosaccharides inhibit endothelial cell functions essential for angiogenesis. *PLoS One* 2010;**5**:11644.
9. Gandhi NS, Mancera RL. Heparin/heparan sulphate-based drugs. *Drug Discov Today* 2010;**15**:1058–69.
10. Lever R, Smailbegovic A, Page C. Role of glycosaminoglycans in inflammation. *Inflammopharmacology* 2001;**9**:165–9.
11. Parish CR. The role of heparan sulphate in inflammation. *Nat Rev Immunol* 2006;**6**:633–43.
12. Parish CR. Heparan sulfate and inflammation. *Nat Immunol* 2005;**6**:861–2.

13. Díaz-Nido J, Wandosell F, Avila J. Glycosaminoglycans and b-amyloid, prion and tau peptides in neurodegenerative diseases. *Peptides* 2002;**23**:1323–32.
14. Iozzo RV, San Antonio JD. Heparan sulfate proteoglycans: heavy hitters in the angiogenesis arena. *J Clin Invest* 2001;**108**:349–55.
15. Rosenberg RD, Shworak NW, Liu J, Schwartz JJ, Zhang L. Heparan sulfate proteoglycans of the cardiovascular system. Specific structures emerge but how is synthesis regulated? *J Clin Invest* 1997;**99**:2062–70.
16. Yip GW, Smollich M, Gotte M. Therapeutic value of glycosaminoglycans in cancer. *Mol Cancer Ther* 2006;**5**:2139–48.
17. Rostand KS, Esko JD. Microbial adherence to and invasion through proteoglycans. *Infect Immun* 1997;**65**:1–8.
18. Sawitzky D. Protein–glycosaminoglycan interactions: infectiological aspects. *Med Microbiol Immunol* 1996;**184**:155–61.
19. Wadstrom T, Ljungh A. Glycosaminoglycan-binding microbial proteins in tissue adhesion and invasion: key events in microbial pathogenicity. *J Med Microbiol* 1999;**48**:223–33.
20. Gandhi NS, Mancera RL. The structure of glycosaminoglycans and their interactions with proteins. *Chem Biol Drug Des* 2008;**72**:455–82.
21. Gesslbauer B, Kungl AJ. Glycomic approaches toward drug development: therapeutically exploring the glycosaminoglycanome. *Curr Opin Mol Ther* 2006;**8**:521–8.
22. Volpi N. Therapeutic applications of glycosaminoglycans. *Curr Med Chem* 2006;**13**:1799–810.
23. Aamiri A, Mobarek A, Carpentier G, Barritault D, Gautron G. Effect of a substituted dextran on reinnervation during regeneration of adult rat skeletal muscle. *C R Acad Sci III* 1995;**318**:1037–44.
24. Zuijndorp HM, Smit X, Blok JH, Caruelle JP, Barritault D, Hovius SE, van Neck JW. Significant reduction in neural adhesions after administration of the regenerating agent OTR4120, a synthetic glycosaminoglycan mimetic, after peripheral nerve injury in rats. *J Neurosurg* 2008;**109**:967–73.
25. Garcia-Filipe S, Barbier-Chassefière V, Alexakis C, Huet E, Ledoux D, Kerros ME, Petit E, Barritault D, Caruelle JP, Kern P. RGTA OTR4120, a heparan sulfate mimetic is a possible long-term active agent to heal burned skin. *J Biomed Mater Res A* 2007;**80**:75–84.
26. Barbier-Chassefière V, Garcia-Filipe S, Yue XL, Kerros ME, Petit E, Kern P, Saffar JL, Papy-Garcia D, Caruelle JP, Barritault D. Matrix therapy in regenerative medicine, a new approach to chronic wound healing. *J Biomed Mater Res A* 2009;**90**:641–7.
27. Tong M, Tuk B, Hekking IM, Vermeij M, Barritault D, van Neck JW. Stimulated neovascularization, inflammation resolution and collagen maturation in healing rat cutaneous wounds by a heparan sulfate glycosaminoglycan mimetic, OTR4120. *Wound Repair Regen* 2009;**17**:840–52.
28. Groah SL, Libin A, Spungen M, Nguyen KL, Woods E, Nabili M, Ramella-Roman J, Barritault D. Regenerating matrix-based therapy for chronic wound healing: a prospective within-subject pilot study. *Int Wound J* 2011;**8**:85–95.
29. Agren MS, Werthén M. The extracellular matrix in wound healing: a closer look at therapeutics for chronic wounds. *Int J Low Extrem Wounds* 2007;**6**:82–97.
30. Hodde JP, Johnson CE. Extracellular matrix as a strategy for treating chronic wounds. *Am J Clin Dermatol* 2007;**8**:61–6.
31. Desgranges P, Barbaud C, Caruelle JP, Barritault D, Gautron J. A substituted dextran enhances muscle fiber survival and regeneration in ischemic and denervated rat EDL muscle. *FASEB J* 1999;**13**:761–6.
32. Yamauchi H, Desgranges P, Lecerf L, Papy-Garcia D, Tournaire MC, Moczar M, Loisançe D, Barritault D. New agents for the treatment of infarcted myocardium. *FASEB J* 2000;**14**:2133–4.
33. Rouet V, Hamma-Kourbali Y, Petit E, Panagopoulou P, Katsoris P, Barritault D, Caruelle JP, Courty J. A synthetic glycosaminoglycan mimetic binds vascular endothelial growth factor and modulates angiogenesis. *J Biol Chem* 2005;**280**:32792–800.
34. Alexakis C, Mestries P, Garcia S, Petit E, Barbier V, Papy-Garcia D, Sagot MA, Barritault D, Caruelle JP, Kern P. Structurally different RGTA modulate collagen-type expression by cultured aortic smooth muscle cells via different pathways involving fibroblast growth factor-2 or transforming growth factor-beta1. *FASEB J* 2004;**18**:1147–9.
35. Rudolph R, Suzuki M, Luce JK. Experimental skin necrosis produced by adriamycin. *Cancer Treat Rep* 1979;**63**:529–37.
36. Tong M, Zbinden MM, Hekking IJ, Vermeij M, Barritault D, Van Neck JW, RGTA OTR. 4120, a heparan sulfate proteoglycan mimetic, increases wound breaking strength and vasodilatory capability in healing rat full-thickness excisional wounds. *Wound Repair Regen* 2008;**16**:294–9.
37. Mangoni M, Yue XL, Morin C, Violot D, Frascogna V, Tao YG, Caruelle JP, Huang QF, Li P, Barritault D, Biti G, Bourhis J. A heparan mimetic of the RGTA family protects mice from radiation-induced mucositis. *Int J Radiat Oncol Biol Phys* 2009;**74**:1242–50.
38. Barritault D, Allaire E, Louissaint T, Kichenin K, Godeau B, Becquemin JP, Desgranges P. Matrix therapy in vascular pathology: first pilot study to evaluate RGTA Caciqliq 20. Abstract at Toronto 2nd World Union of Wound Healing Society meeting; 2008; Toronto, Canada. URL: <http://www.wuwhs.com/congress2008/abstracts/abstractPW193.html> [accessed on 15 August 2011].